ESD
Endoscopic Submucosal Dissection
— Techniques —



Dr. Hiroyuki Ono — Endoscopy and GI Oncology Division, Shizuoka Cancer Center

Dr. Takuji Gotoda — Endoscopy Division, National Cancer Center Hospital, Tokyo

Dr. Tsuneo Oyama — Department of Gastroenterology, Saku Central Hospital

Dr. Naohisa Yahagi — Department of Gastroenterology and Digestive Endoscopy unit, Toranomon Hospital

Dr. Haruhiro Inoue, Dr. Yoshitaka Sato — Digestive Disease Center, Showa University Northern Yokohama Hospital

Dr. Toshihiko Doi — Digestive Endoscopy and Gastrointestinal Oncology Division, National Cancer Center Hospital East

Supported by: Olympus Medical Systems Corp.

Prologue

~Development of ESD Devices~

ITknife Technique <I>

Hiroyuki Ono Endoscopy and GI oncology Division, Shizuoka Cancer Center

The concept of the ITknife originated with Dr. Koichi Hosokawa, formerly of the National Cancer Center Hospital in Tokyo (and now at the Togariishi Clinic in Nagano). At the time, I was also working at the National Cancer Center Hospital and, together with Dr. Hosokawa, experimented with the ITknife on dogs. Our goal was to enable en-block resection by means of EMR and we looked for a knife that would perform horizontal cutting only without deep cutting. So we ordered an ITknife fabricated by attaching an insulating tip at the distal end of a needle knife. Once the knife had been developed, I worked in cooperation with Dr. Gotoda, a resident three years behind me, to establish an ITknife technique for clinical applications.

ITknife Technique <II>

Takuji Gotoda Endoscopy Division, National Cancer Center Hospital, Tokyo

I became a resident in the Endoscopy Division of the National Cancer Center Hospital in Tokyo in June 1995. Under the leadership of Dr. Koichi Hosokawa (now at the Togariishi Clinic in Nagano) who is a well-known idea man, I participated in a project aimed at improving the needle knife for use in the ERHSE technique. After trial development of the distal tip for prevention of perforation using various materials,we eventually came up with what is now known as the ITknife. When I completed the rotation, I returned to the Endoscopy Division in 1996 to find the chief resident, Dr. Hiroyuki Ono (now Director of the Endoscopy and GI Oncology Division, Shizuoka Cancer Center), working hard to apply the ITknife in actual EMR operations. As there were no residents who specialized in the upper gastrointestinal tract, I was lucky enough to attend Dr. Ono in this field and obtain experience in the use of the ITknife. I had originally become a National Cancer Center resident because I had wanted to perform colonoscopy, and it was only by chance and good luck that I encountered Dr. Hosokawa, Dr. Ono and the ITknife.

HookKnife Technique

Tsuneo Oyama Department of Gastroenterology, Saku Central Hospital

It started when I intentionally bent the distal end of a needle knife myself, thinking that I would be able to incise and dissect the mucosa more safely if the distal end of a needle knife were bent into an L-shape so that it could hook the mucosa before cutting. Later, I asked Olympus to create a similar prototype, which was later provided with a rotation function and eventually commercialized.

FlexKnife Technique

Naohisa Yahagi Department of Gastroenterology, Toranomon Hospital

In the beginning, we were looking for a knife that was flexible, easy to manipulate and had an adjustable distal end length. We noticed that the distal end of the thin snare (SD-7P) can be used to incise the mucosa and initially performed ESD as a thin snare technique. But this technique brings with it such problems as variation of the distal end length or splitting of the wire's distal end during a procedure. We therefore created the FlexKnife by increasing the wire strength and adding a stopper mechanism.

TriangleTipKnife Technique

Haruhiro Inoue / Yoshitaka Sato Digestive Disease Center, Showa University Northern Yokohama Hospital

A hook is also one of the basic surgical devices in endoscopic surgery (laparoscopic cholecystectomy). ESD also uses a hook, but axis alignment was often difficult with flexible scopes. So we designed the TriangleTipKnife which has three distal ends in three directions so to speak. This functions like a hook that does not need axis alignment.

ITknife Supporting Devices

Toshihiko Doi Digestive Endoscopy and Gastrointestinal Oncology Division, National Cancer Center Hospital East

ESD has proven that it can expand the indications and improve the curability of EMR. However, ESD's practice remains limited (due to accidents and complexity) and it is relegated to a minor position in the hierarchy of EMR procedures. When considering how to establish ESD as a more universal technique, keep in mind that the basic endoscopic treatment is biopsy. This led us to the idea that we should try to develop a mucosal incision technique that resembles biopsy. What usually throws off first-time users of the ITknife is that, while previous treatment devices are manipulated with a pulling action, the ITknife technique depends on advanced scope maneuvering except for the sections that can be cut by pulling the ITknife. In particular, the actions required to make introduction holes with a needle knife tend to be very unstable.
So, keeping in mind that biopsy-style manipulations are the cornerstone of any endoscopic treatment, I began to search for a way to perform ESD using similar manipulations. My first thought was that it would be safer if a hole could be made by grasping the mucosa via the introduction holes and then supplying current. We designed the HotClaw with as a tool for lifting the mucosa for incision and dissection.
Our intention was to reduce the risk of perforation by applying an upward force instead of downward cutting force. For the Coagrasper, we focused on how to stop bleeding — one of the most critical complications associated with ESD — more quickly and more effectively.
Some hospitals still use the hot biopsy forceps for hemostasis, but as a device exclusively designed for hemostasis, the Coagrasper's shape and electrical characteristics are suitable for hemostasis. Our goal has always been to develop an ITknife technique that is safe and that can be easily performed by beginners.



ITknife Techniqu

Dr. Hiroyuki Ono
Endoscopy and GI Oncology Division, Shizuoka Cancer Center

Interview With The Expert

Q. What are the advantages of the ITknife?

A. **First of all, It has an insulation tip at the distal end that makes it hard to cut in the perpendicular direction, minimizing the likelihood of cutting too deeply. Secondly, the entire blade is used for cutting. So cutting speed should be higher than with other. Thirdly, it is also capable of horizontal cutting, so once you get used to it you can use this single device for both mucosal incision and submucosal dissection.**

Q. What are the weak points of the ITknife (assuming there are any)?

A. **Horizontal cutting is difficult so it takes some practice getting used to, and cutting by jerking up the knife is almost impossible. Also, it may be very difficult to resect a lesion in the greater curvature in the middle or upper body because such a lesion forces the knife into a perpendicular position relative to the mucosa.**

Q. Under what conditions do you also use other devices?

A. **The HotBite invented by Dr. Doi may also be useful because it ensures safety in the precutting for insertion of the ITknife. The ITknife is an excellent device, but I encourage you not stick to a single device but to use whichever device is most appropriate under the circumstances.**

Applicability of the ITknife

■Difficulty per region

○:Easy. No mark: Ordinary. △:Difficult.

Cardiac region			Posterior wall of upper body			Lesser curvature of lower body			Greater curvature of antrum	○	
Fornix	△		Lesser curvature of middle body			Greater curvature of lower body			Anterior wall of antrum	○	
Lesser curvature of upper body			Greater curvature of middle body	△		Anterior wall of lower body			Posterior wall of antrum	○	
Greater curvature of upper body	△		Anterior wall of middle body			Posterior wall of lower body			Pyloric ring	△	
Anterior wall of upper body			Posterior wall of middle body			Lesser curvature of anterior wall					

Note for beginners: It is recommended to start a trial procedure on a minor lesion in the anterior or posterior wall in the antrum or in the greater curvature. Once you have become accustomed to the procedure (after 20 or 30 cases), you can tackle larger and more difficult lesions. If the scope cannot approach the lesion (for example, when it is located in the angulus), the procedure can sometimes be facilitated by switching to thicker, sturdier scope such as a 2-channel scope or a treatment scope.

e <I>

Sedation

IV anesthesia	Premedication	General anesthesia	Monitoring
Buscopan, Opistan, Cercine	No	No	SPO2, ECG, blood pressure

Electrosurgical Unit	ICC200 (Erbe)

Marking

Device	Caution	Setting
Needle knife	Use the 20 W coagulation wave. If the power is higher, bleeding or perforation may result.	Forced, 20W

Local injection



	Epinephrine	Indigo carmine	
Saline	Yes (Dilute by 200 times.)	Yes (Moderate amount)	Merit: Low price. Demerit: Short lifting time.
Reason for use of indigo dye: Dyeing the submucosal layer facilitates recognition of the dissected region. The dye should be relatively light.			

Circumferential incision

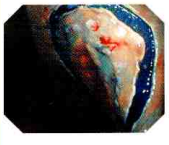

	Device	Caution	Setting
Precut	Needle knife	The 120 W output is best for cutting.	Auto Cut, 120W, Effect3 (Set Forced, 50 W for coagulation.)
Circum-ferential incision	ITknife		Endo Cut, 120W, Effect 3 Auto Cut, 120W, Effect 3 (Set Forced, 50 W for coagulation.)

Submucosal dissection



Device	Caution	Counter traction	Setting
ITknife	The 120 W output is best for cutting.	Tension is applied by twisting the scope or attaching an attachment.	Endo Cut, 120W, Effect 3 (Set Forced, 50 W for coagulation.)

Hemostasis

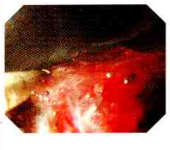

Device		Setting
ITknife		Forced, 50W
Hot biopsy		Soft Coag., 80W
Other	If the above devices do not work well, the HSE or clip can be used.	

Preventive hemostasis

The visible blood vessels are coagulated before they can bleed.

Perforation measure

Method	Timing	Tip
Clipping	Immediately after perforation, if possible. If not, after the mucosa has been dissected to a degree in which the clip does not hinder operation.	Clip to align the tumor bottoms. If the perforation is big, it is easier to patch it with the omentum.

The setting values are those determined as of September 1, 2005.

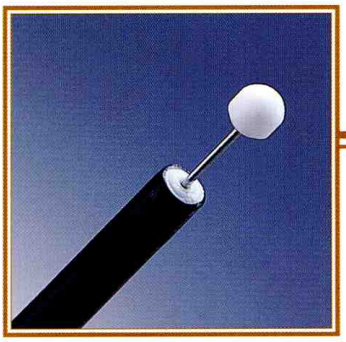

ITknife Techniqu

Dr. Takuji Gotoda
Endoscopy Division, National Cancer Center Hospital, Tokyo

Interview With The Expert

Q. What are the advantages of the ITknife?

A. Perforation is not completely avoided, but its pointed distal ends make it much safer than other devices. The ITknife can incise or dissect a long section with each stroke, so it helps reduce the procedure time. However, since I have never performed EMR using other devices on their own, I cannot really compare the advantages and disadvantages. All I can say that the device I am most familiar with in ESD is the ITknife.

Q. What are the weak points of the ITknife (assuming there are any)?

A. During incision, the pulling action is relatively easy, but you'll need a certain level of skill in scope maneuvering to cut the mucosa in the horizontal direction. Also, incision in the longitudinal direction may look simple on video but you actually need to apply a downward force to the scope to push the ITknife blade against the incised surface. This means that incision of a region where the ITknife blade should be oriented perpendicularly, for example, incision of a lesion in the greater curvature or the angulus, is not so easy. On the other hand, incision of a lesion in the cardiac region or lesser curvature of the stomach body is relatively easy. Just like when you cut a steak, you cannot cut well if you hold the knife perpendicularly; you have to lay the knife down to cut the steak. In any case, I always try for better, even if it's not the best, positioning of the scope by twisting it or adjusting its angulation to the left and right in order to obtain an image so that tension is applied to the incised surface. Beginners seem to have a lot of trouble with dissection after incision because the groove they cut around the lesion tends to be too shallow due to fear of perforation. Anyway, I believe everything depends on maneuvering the scope so that tension can be applied in the optimum direction. It is also useful to remember that the optimum position varies depending on the amount of air, elapsed time and patient's position even when incising the same region. After all, the ITknife manipulation for dissection requires you to get well accustomed to it. Here, the optimum positioning is more critical than when you incise the surroundings. With the ITknife technique, the optimum positioning for dissection often means the possibility of blind operation. I think it is rather rare that the ITknife blade contacts the dissection surface with optimum tension under the direct-vision condition. In fact, it is necessary to create a condition in which the optimum tension for cutting is applied by identifying the lumen status from the air amount and remembering the direction of the stomach wall curve, and perform dissection by pulling or twisting the scope in a blind operation. As manipulations that are never used in ordinary upper gastroenterological examinations are required for both incision and dissection, anyone may be perplexed in the beginning.

Q. Under what circumstances do you also use other devices?

A. When optimum tension for incision and dissection cannot be obtained because the ITknife blade is perpendicular, I replace the ITknife with a device that cuts with the distal end, such as a needle knife. Also, when cutting debris covers the dissection surface, making it difficult to confirm the scope maneuvering direction, I use a distal attachment, slipping it into the submucosal layer to ensure the field of view and confirm the direction of dissection. This operation is also effective for applying tension to the dissection surface as well as to ensure the view.

Applicability of the ITknife

Difficulty per region

○:Easy. No mark: Ordinary. △:Difficult.

Cardiac region	○	Possibility of close-up in the look-up approach.	Posterior wall of upper body	○		Lesser curvature of lower body	○	Sometimes hard to cut due to long distance.	Greater curvature of antrum	○	
Fornix	△		Lesser curvature of middle body	○		Greater curvature of lower body			Anterior wall of antrum	○	Because the channel is located on the left.
Lesser curvature of upper body	○		Greater curvature of middle body	△		Anterior wall of lower body			Posterior wall of antrum	○	
Greater curvature of upper body	△		Anterior wall of middle body			Posterior wall of lower body	○	Close-up is possible.	Pyloric ring		
Anterior wall of upper body			Posterior wall of middle body			Lesser curvature of anterior wall	○				

Sedation

IV anesthesia	Premedication	General anesthesia	Monitoring
Yes	Pentazocine 15 mg + Midazolam 5 mg	Depends. (Desirable if possible)	Yes

Electrosurgical Unit	ICC200 (Erbe)	VIO-300D (Erbe)

Marking

Device		Setting	
Needle knife		Forced, 20W	Swift Coag. 50W Effect 4

Local injection

	Epinephrine	Indigo carmine	
Saline	Yes (Dilute by 10,000 times.)	Yes	Merit: Low price. Demerit: Short lifting time.
Glyceol	Yes (Dilute by 10,000 times.)	Yes	Merit: Long-lasting lifting

Sm/mp determination: Confirm the white fascia on the muscular layer surface and dissect the area immediately above it.

Circumferential incision

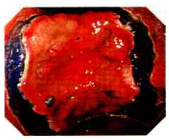

	Device	Caution	Setting	
Precut	Needle knife		Endo Cut, 80W, Effect 3	EndoCut(I) – Effect 2 Cut duration 3 Cut interval 3 DryCut 50W Effect 4
Circum-ferential incision	ITknife	If horizontal operation is difficult or there is heavy scarring, also use the HookKnife and/or FlexKnife.	Endo Cut, 80W, Effect 3	EndoCut(I) – Effect 2 Cut duration 3 Cut interval 1 DryCut 50W Effect 4

Submucosal dissection

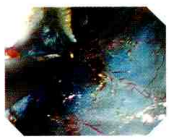

	Device	Knack	Counter traction	Setting	
	ITknife	With horizontal operation and scarring, a point-cutting device such as a needle knife cuts better than the line-cutting device such as an ITknife.	• Attach a distal attachment. • Lift slightly using the sheath of the ITknife. • Blind cutting.	Endo Cut, 80W, Effect 3	EndoCut(I) – Effect 2 Cut duration 3 Cut interval 1 DryCut 50W Effect 4 Swift Coag., 50W Effect 4
	Needle knife			Endo Cut, 80W, Effect 3	DryCut 50W Effect 4

Hemostasis

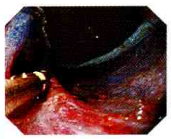

	Device	Caution	Setting	
	ITknife	For venous bleeding.	Forced, 50W	Swift Coag., 50W Effect 4
	Coagrasper / Hot biopsy	Venous bleeding: Possible to confirm hemostasis by grasping. If hemostasis is performed without confirmation, carbonization will make incision difficult.	Soft Coag., 80W	Soft Coag., 80W Effect 5
Preventive hemostasis	ITknife	Small vessels: Can be crushed directly with the ITknife.	Forced, 50W	Swift Coag., 50W Effect 4
	Coagrasper / Hot biopsy	Thick bleeding vessels: Grasp firmly with the hot biopsy forceps and, after confirming hemostasis, supply the current.	Soft Coag., 80W	Soft Coag., 40-80W Effect 5

Perforation measure

Method	Timing	Tip
Clipping	Later	Since perforations in ESD are often between 1 and 2 mm, they can usually be stopped with a single clip. However, to prevent the clipping from hindering cutting thereafter, some dissection is required to enable clipping by confirming the perforation section.

The setting values are those determined as of September 1, 2005.

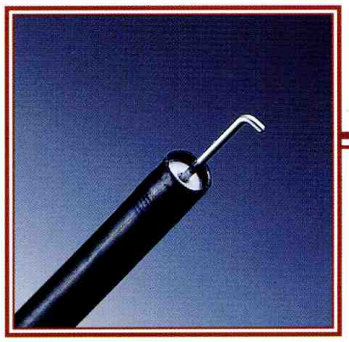

HookKnife Techn

Dr. Tsuneo Oyama
Department of Gastroenterology, Saku Central Hospital

Interview With The Expert

Q. What are the advantages of the HookKnife?

A. Above all, it's safer than a needle knife because it hooks the mucosa for incision and dissection so there's less invasion of deep tissues. The rotary function provides another advantage, the ability to align the knife horizontally or vertically. The back of the HookKnife can be used for marking to reduce the risk of perforation. Safety during an operation can be ensured by attaching an attachment to the scope's distal end to maintain the field of view and by suctioning the mucosa into the attachment before supplying current. The capability to perform dissection by observing the submucosal layer under direct vision enables precoagulation. It is nice to be able to perform dissection with a good view and without bleeding.

Q. What are the weak points of the HookKnife (assuming there are any)?

A. The hook at the distal end has a length of 1.3 mm. An unavoidable disadvantage of this is that the distance per cut is not very long.

Q. Under what circumstances do you also use other devices?

A. I use a needle knife for circumferential incision. The needle knife is convenient in that it can be used as if jerking up.Also, the ITknife and FlexKnife have a higher vertical incision speed so I sometimes use them instead of the HookKnife.

Applicability of the HookKnife

■Difficulty per region

○:Easy. No mark: Ordinary. △:Difficult.

Cardiac region	△		Posterior wall of upper body	○		Lesser curvature of lower body	○		Greater curvature of antrum		
Fornix	△		Lesser curvature of middle body	○		Greater curvature of lower body	△		Anterior wall of antrum	○	
Lesser curvature of upper body			Greater curvature of middle body			Anterior wall of lower body	○		Posterior wall of antrum	○	
Greater curvature of upper body	△		Anterior wall of middle body	○		Posterior wall of lower body	○		Pyloric ring	△	
Anterior wall of upper body	○		Posterior wall of middle body	○		Lesser curvature of anterior wall	○				

Note for beginners: 1) It is important to begin by viewing the procedures performed by experts. 2) It is recommended to start by treating a lesion 2 mm or smaller UL (-). 3) After you've had experience with about 10 cases, it is recommended to observe procedures performed by others again.

Sedation

IV anesthesia	Premedication	General anesthesia	Monitoring
Yes	Midazolam 5-7.5 mg + Butorphanol 0.5 mg	No	Yes

Marking

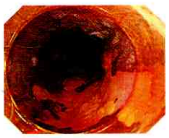

Electrosurgical Unit	ICC200 (Erbe)	VIO-300D (Erbe)	PSD-60 (Olympus)
Device	**Caution**	**Setting**	
HookKnife (Marking using the back)	Marking using the back of the HookKnife helps reduce the risk of perforation.	Forced, 40W	Forced, 40W, Effect 3	Forced, 40W, Effect 1

Local injection

	Epinephrine	Indigo carmine	
Glyceol	Yes	No	Esophagus: 200x diluted. Stomach: 20x diluted. Merit: Relatively long period of lifting (Equiv. to 20% glucose)
Sodium hyaluronate	Yes	No	Colon: Use hyaluronic acid and epinephrine. Merit: Strongest retention force.

Even when transparent local injection fluid is used, the muscular layers can be observed as a thick, white, cloudy layer and the submucosal layer as a transparent layer. The transparency of blood vessels in the sm layer is better when indigo carmine is not added. When indigo is added, the excised specimen is dyed in blue.

Circumferential incision

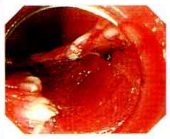

Device	Caution	Setting		
Needle knife	The Endo Cut mode advances incision little by little and allows mistakes to be avoided even when knife control is insufficient. The Auto Cut mode performs incision quickly, leaving a sharp opening with little thermal degradation.	Beginner: Endo Cut, 60W, Effect 3 Skilled: Auto Cut, 60W, Effect 3	DryCut, 60W, Effect 3	Auto Cut, 60W, Effect 5
HookKnife				

Submucosal dissection

Device	Caution	Counter traction	Setting		
HookKnife	With a large lesion, dissection using the ITknife is quicker than using the HookKnife alone. When a big blood vessel is exposed, supply 60 W current in the APC mode. During discharge, slight magnification is required to obtain a detailed view of blood vessels.	The distal end attachment (D-201) is used. The distal attachment is used with the esophagus. The suction technique can be used for dissection. A clip with a cord is also used.	Forced, 60 W APC mode, 60 W	DryCut, 60W, Effect 3 Spray Coag., 40W, Effect 3	Forced, 60W, Effect 1 Forced, 40W, Effect 2

Hemostasis

Device	Caution	Setting		
HookKnife		APC mode, 60 W	Spray Coag., 40W, Effect 3	Forced, 60W Effect 2
Hot biopsy forceps	If bleeding continues, the grasped position may be erroneous; it is important to grasp another position.	Soft Coag., 50-60 W (2-3 sec. current supply) Forced, 40 W (0.1 sec. current supply)	Soft Coag., 50-60W	Soft Coag., 50W, Effect 4

Preventive hemostasis

HookKnife	Small blood vessel of ca. 1 mm: Hook with the HookKnife and perform coagulation hemostasis in the APC mode at 60 W. During discharge, slight magnification is required to obtain detailed view of blood vessels.
Hot biopsy forceps	Relatively big blood vessel of 2 mm or less: Grasp the vessel with a hot biopsy forceps and supply Soft Coag. mode, 40 W current for 2 to 3 sec,

Perforation measure

Method	Timing	Tip
Clipping	Since immediate clipping makes the subsequent operation impossible, dissection should be advanced by a certain degree before clipping.	Since perforations with the HookKnife are usually as small as about 1 x 3 mm, they can usually be stopped with a single clip. Air leak can be expected to be very low.

The setting values are those determined as of September 1, 2005.

FlexKnife Techni

Dr. Naohisa Yahagi

Department of Gastroenterology and Digestive Endoscopy unit, Toranomon Hospital

Interview With The Expert

Q. What are the advantages of the FlexKnife?

A. **One of the biggest advantages of this device is that it is easy to manipulate. Both the sheath and wire are flexible, so cutting in the vertical, horizontal or oblique directions can be done easily. The cuff at the distal end of the sheath works to prevent penetration of the knife into the deep tissues. Basically, a single FlexKnife can be used for the entire procedure from marking to dissection.**

Q. What are the weak points of the FlexKnife (assuming that there are any)?

A. **Having to fine-adjust the distal end extrusion length may be difficult for beginners. Also, since force cannot be transmitted effectively over longer distances, it is necessary to use the FlexKnife with a scope like the M-Scope. The cut may be difficult when the tissue is suspended and tends to slip off.**

Q. Under what circumstances do you also use other devices?

A. **I use the HookKnife, for example when mucosa is left at only one point at the end of dissection. I also use the HookKnife when dissecting the deep submucosal layer or when mobility is restricted because it is quicker.**

Applicability of the FlexKnife

■Difficulty per region

○:Easy. No mark: Ordinary. △:Difficult.

Cardiac region	△		Posterior wall of upper body	△	Propensity for bleeding.	Lesser curvature of lower body		When the angulus is opened wide, the device tends to lose contact with the mucosa. Transmission of force is difficult in this case.	Lesser curvature of anterior wall	○	
Fornix	△		Lesser curvature of middle body	○					Greater curvature of antrum	○	
Lesser curvature of upper body			Greater curvature of middle body	△	Bleeding will result in pools of blood.	Greater curvature of lower body			Anterior wall of antrum	○	
Greater curvature of upper body	△	Bleeding will result in pools of blood.	Anterior wall of middle body	△		Anterior wall of lower body			Posterior wall of antrum	○	
Anterior wall of upper body	△		Posterior wall of middle body			Posterior wall of lower body			Pyloric ring	△	

que

Sedation

IV anesthesia	Premedication	General anesthesia	Monitoring
Yes (Less than 4 hours)	Pethidine hydrochloride 15 mg + Diazepam 5 mg (As required)	Yes (If more than 4 hours)	Yes (Performed with all cases)

Electrosurgical Unit	ICC200 (Erbe)	PSD-60 (Olympus)

Marking

Device	Caution	Setting	
FlexKnife	The flexible device deals easily with any bend. The extrusion length can be adjusted freely, so perforation does not occur.	Soft Coag., 50W	Soft Coag., 50W, Effect 5

Local injection

	Epinephrine	Indigo carmine	
Sodium hyaluronate	Yes (Dilute by 10,000 times)	Yes	Merit: Best among the currently available local injection agents. The even tension leaves very clean opening. Lifting time is long. Indispensable for colons. Demerit: High price and complicated dilution.
20% glucose	Yes (Dilute by 10,000 times)	Yes	Merit: Dilution not required (direct use of an ampoule product). Enough lifting time. Light tissue damage and relatively low price.

The sm layer is dyed blue by the indigo carmine. Even when the tissue is subjected to the burn effect, the layer is distinguishable thanks to the indigo carmine.

Circumferential incision

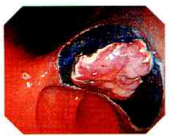

Device	Caution	Setting	
FlexKnife	The Endo Cut mode cuts rhythmically and distal end control is easy.	Endo Cut, 80W, Effect 3	Endo Cut, 120W, Effect 3

Submucosal dissection



Device	Caution	Counter traction	Setting	
FlexKnife	As the Endo Cut mode cuts well but tends to cause bleeding, use the Forced Coag. mode to perform dissection while preventing bleeding. Scissor forceps (FS-3L-1) is used in hard-to-cut tissues such as scarring.	Make use of the rolling up caused by the gravity. Greater curvature: Use a hood with obliquely cut tip. Use a distal attachment.	Forced, 40W	Forced, 50W, Effect 1-2

Hemostasis

Device	Operation	Other Note	Setting	
FlexKnife	Venous bleeding: Simply press the coagulation pedal.	Confirm the bleeding site using the water jet function.	Forced, 40W	Forced,50W, Effect 1-2
Hemostatic forceps	Arterial bleeding: Use hemostatic forceps.		Soft Coag., 50W	Soft Coag., 50W, Effect 5

Preventive hemostasis

Small blood vessels: Supply current from a non-contact condition at a little distance.	FlexKnife (Forced)	
If bleeding cannot be stopped using the above mode: Supply current from a non-contact condition at a little distance.	APC mode, 60 W	
Big blood vessels: Soft coagulation using hemostatic forceps.	Soft Coag., 40-60 W	

* The Forced and APC modes enable instant hemostasis but care is required to avoid scorching and re-bleeding. *Soft coagulation wave should be applied for a longer period.

Perforation measure

Method	Timing	Tip
Clipping	Immediately after discovering perforation.	The clip may hinder subsequent operations. Extrude the distal end of the FlexKnife only a little or slide the scissor forceps above the clip and dissect that part only.

The setting values are those determined as of September 1, 2005.



TriangleTipKnife T

Dr. Haruhiro Inoue / Dr. Yoshitaka Sato
Digestive Disease Center, Showa University Northern Yokohama Hospital

Interview With The Expert

Q. What are the advantages of the TriangleTipKnife?

A. First, it does not need any kind of axis alignment. It can hook effectively in any direction.

Q. What are the weak points of the TriangleTipKnife (assuming there are any)?

A. When there is serious fibrosis in submucosal dissection, it is better to use a hook because it has a thinner distal end than the TriangleTipKnife.

Q. Under what conditions do you use other devices as well?

A. If the dissected part of the mucosa starts dangling when you are about to achieve resection, it's easier to complete the procedure using the ITknife or conventional snare.

Applicability of the TriangleTipKnife

Difficulty per region

○:Easy. No mark: Ordinary. △:Difficult. ▲:Very difficult.

Cardiac region	△		Posterior wall of upper body	▲		Lesser curvature of lower body			Greater curvature of antrum	○	
Fornix	▲		Lesser curvature of middle body			Greater curvature of lower body			Anterior wall of antrum	○	
Lesser curvature of upper body			Greater curvature of middle body			Anterior wall of lower body			Posterior wall of antrum	○	
Greater curvature of upper body	△		Anterior wall of middle body			Posterior wall of lower body	△		Pyloric ring		
Anterior wall of upper body			Posterior wall of middle body	△		Lesser curvature of anterior wall	○				

Note for beginners: The most difficult regions are in the upper part and posterior wall side of the stomach

echnique

Sedation	IV anesthesia	Premedication	General anesthesia	Monitoring
	Opystan, 35 mg + Horizon 10 mg	Buscopan 1 A	If the procedure is expected to take more than 2 hours, general anesthesia should be applied.	SPO2, ECG and blood pressure with all cases.

Electrosurgical Unit	ICC200 (Erbe)	PSD-60 (Olympus)

Marking		Device	Caution	Setting	
	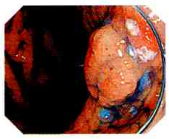	TriangleTip Knife	Keep TriangleTipKnife inside the sheath, and then touch the mucosa lightly and briefly apply current.	Forced, 30W	Coag. (Forced), 60 W, Effect 1

Local injection		Epinephrine	Indigo carmine	
	Saline	Yes (Dilute by 200,000 times.)	Yes (Moderate amount)	Merit: Low price. Demerit: Short lifting time.
	Sodium hyaluronate	Yes (Dilute by 3 times.)	Yes	Merit: Long lifting time. Demerit: High price.
	Explanation:Use saline for circumferential incision. For submucosal dissection, use sodium hyaluronate to achieve sufficient lifting to ensure the field of view and perform dissection with the tip.			

Circumferential incision		Device	Caution	Setting	
		TriangleTip Knife	For precutting, place the triangular tip gently against the mucosa and briefly apply current in the Endo Cut or Auto Cut mode. Once the muscular layer of the mucosa has been cut and the submucosal layer is exposed, advance the mucosal incision along at that depth. For circumferential incision, apply tension to the mucosa using a distal attachment, hook the tip and apply current to advance the incision. If tension is insufficient, the tip may hook properly. When using the PSD-60, bleeding can be reduced and cutting can be made smoother by setting the mode to Coag. (Forced), output to 80 W and Effect to 2.	Endo Cut/ Auto Cut 120 W, Effect 3	Endo Cut 120 W, Effect 3 Auto Cut 120 W, Effect 5-6 Coag. (Forced) 80 W, Effect 2

Submucosal dissection		Device	Caution	Setting	
		TriangleTip Knife	Using a distal attachment, place the scope tip in the submucosal layer and, while applying tension and observing the site under direct vision, apply current and perform dissection. Be careful not to catch the muscular layer during this procedure. Use sodium hyaluronate as the local injection agent.	Forced. 60 W	Coag. (Forced), 80 W, Effect 2

Hemostasis		Device	Caution	Setting	
		TriangleTip Knife	If gushing bleeding occurs, bring the triangular tip in contact with the bleeding point and start coagulation for hemostasis. In this case, it is important to confirm the bleeding point accurately.	Forced. 60 W	Coag. (Forced), 80 W, Effect 2
		Hot biopsy	If bleeding cannot be stopped with the tip of the TriangleTipKnife, grasp the bleeding point with the Coagrasper and apply current in the Soft Coagulation mode for 2 to 3 seconds. In this case, too, it is important to confirm the bleeding point accurately.	Forced. 80 W	Soft Coag., 80 W, Effect 6-8

Preventive hemostasis					
		TriangleTip Knife	If bleeding cannot be stopped with the tip of the TriangleTipKnife, grasp the bleeding point with the Coagrasper and apply current in the Soft Coagulation mode for 2 to 3 seconds. In this case, too, it is important to confirm the bleeding point accurately.	Forced. 60 W	Coag. (Forced), 80 W, Effect 2
		Hot biopsy		Forced. 80 W	Soft Coag., 80 W, Effect 6-8

Perforation measure	Method	Timing
	If the perforation is as small as a pinhole, stop it with a clip for conservative treatment.	The basic idea is to stop perforation with a clip immediately after it occurs. If clipping is difficult, it is sometimes better to advance incision/dissection a little further before clipping.

The setting values are those determined as of September 1, 2005.



ITknife Supportin

Dr. Toshihiko Doi

Digestive Endoscopy and Gastrointestinal Oncology Division,
National Cancer Center Hospital East

Interview With The Expert

Q. What are the advantages of the devices you invented?

A. **To use them you only need to be familiar with standard biopsy techniques. They can minimize bleeding and are designed with full consideration for safety. The HotClaw is suitable for connecting the incised parts or when approach using the ITknife is difficult. The HotBite and Coagrasper are the supporting devices for use in ESD. I hope they are used as required during the ESD procedure.**

Q. What are the weak points of the devices you invented (assuming there are any)?

A. **In principle, these devices can be used in any position in which biopsy is possible. However, in positions where biopsy is difficult (with which the forceps should be positioned in the tangential direction), inevitably these devices are difficult to use as well. In addition, it may be difficult to cut in regions with strong fibrosis Considering the relatively strong degradation due to coagulation, I recommend them as auxiliary devices until electrosurgical systems have been improved enough to prevent degradation. Nevertheless, the ITknife can cut such sites relatively easily and safely. It is the best from the viewpoint of the cutting speed in the vertical direction. With any of these devices, grasping too much mucosa causes the electrical resistance to drop and cauterization may become impossible by supplying current. This is a point that should be noted in their use.**

Q. Under what circumstances do you also use other devices?

A. **At present, I employ the two devices (note: HotBite and Coagrasper) in almost all ESD procedures. For vertical cutting, the ITknife is faster so I generally use the ITknife. I use other devices as auxiliary devices for the present, but I believe that the electrical risk is lowest with the ITknife. Using the appropriate device for a specific purpose is important, but there exists an affinity for certain devices, just like there are surgeons who are good at Cooper's hernia, surgeons who are good at electrocautery, etc. You should not pay too much attention to "rumors" but select the device you use from the viewpoint of radical curability and safety.**

Applicability of the ITknife Supporting Devices

■Difficulty per region

○:Easy. No mark: Ordinary. △:Difficult.

Cardiac region	△	Easy to use the hood after circumferential incision.	Posterior wall of upper body	○	Facilitated by using a 2CH scope. Bleeding should be controlled.	Lesser curvature of lower body	○	Facilitated by using a 2CH scope. Can also be slightly retroflexed in the antrum.	Greater curvature of antrum	○	The HotClaw can be used on the anal side.
Fornix	△	Problem in the distance from the scope.	Lesser curvature of middle body	○		Greater curvature of lower body	△	Easy by using the HotClaw as the main device. SB can be applied after circumferential incision.	Anterior wall of antrum	○	
Lesser curvature of upper body	△	Circumferential incision should be relatively shallow.	Greater curvature of middle body	△	Easy by using the HotClaw as the main device. SB can be applied after circumferential incision.	Anterior wall of lower body	○		Posterior wall of antrum	○	Facilitated by using a 2CH scope.
Greater curvature of upper body	△	Easy by using the HotClaw as the main device.	Anterior wall of middle body	△		Posterior wall of lower body	○		Pyloric ring	△	The HotClaw can be used on the anal side.
Anterior wall of upper body	△	Facilitated by using a 2CH scope.	Posterior wall of middle body	○	Can also be slightly retroflexed in the antrum.	Lesser curvature of anterior wall	○				

Note for beginners: These devices are basically recommended for circumferential incision of a 30-mm-or-less differentiated carcinoma with preoperative diagnosis of m/ul (-). It is essential that the operator be able to continue the treatment using another method, in addition to hemostasis, if ESD turns out to be unmanageable. No attempt to perform ESD should be made if curability is expected to be lower than that of piecemeal resection. It is acceptable for beginners to make holes with the HotBite, connect those holes with the HotClaw and then cut the remaining sections with the ITknife. Beginners should start with lesions that do not require dissection after circumferential incision. Keep in mind that this is an experimental medical procedure and observe maximum consideration for patients' curability as well as safety.

g Devices

Sedation	IV anesthesia	Premedication	General anesthesia	Monitoring
	No in principle (Should always be under supervision of an anesthesiologist)	Buscopan (Dormicum): As required. Opystan + Dormicum: As required	No in principle (Should always be under supervision of an anesthesiologist)	Yes with all cases

Electrosurgical Unit	ICC200 (Erbe)	PSD-60 (Olympus)

Marking

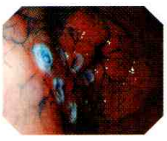

Device	Caution	Setting	
HotBite or Needle knife	HotBite: Use the distal end in the same way as coagulation probe. Low risk of perforation.	Forced, 35W	Forced, 35W Effect 1

Local injection

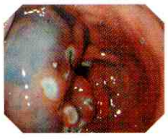

	Epinephrine	Indigo carmine	
Saline	Yes (1 A per 100 cc)	Yes	Merit: Approved by Japanese insurance system. Demerit: Short duration.
Mannitol	Yes (0.5 A per 100 cc)	Yes	When the submucosal layer cannot be lifted easily.

Use of indigo: Recommended in principle.

xxxPre Cutxxx

Device	Caution	Setting	
HotBite		Auto Cut, 120W, Effect 3	Auto Cut, 120W, Effect 5-6
Needle knife		Auto Cut, 120W, Effect 3	Auto Cut, 120W, Effect 4

Circumferential incision

Device	Caution	Setting	
ITknife	Pulling cut direction (2CH scope: An appropriate biopsy port should be used): Overwhelmingly quick, stable incision. Bleeding can be reduced by maintaining the depth of the HotBite.	Endo Cut, 120W, Effect 3 Auto Cut, 120W, Effect 3	Endo Cut, 120W, Effect 3 Auto Cut, 120W, Effect 5-8
HotClaw	Same manipulation as biopsy. Cutting in the lateral direction with respect to the scope axis. Suitable for beginners.		

Submucosal dissection

Device	Caution	Counter traction	Setting	
ITknife	The ITknife contacts the tissue tangentially so the coagulation performance is relatively stable. *A HotBite may also be used with scarring, etc.	Use a 2CH scope. Use a distal attachment and hood.	Endo Cut, 120W, Effect 3 Auto Cut, 120W, Effect 3	Endo Cut, 120W, Effect 3 Auto Cut, 120W, Effect 5-8
HotClaw				

Hemostasis

Device	Caution	Setting	
Coagrasper	2 to 3 sec. current supply.	Forced, 40W	Forced, 40W, Effect 1
ITknife	Initiate coagulation in the middle of incision.	Soft Coag., 50W Forced 40W	Soft Coag., 50W, Effect 4-5 Forced 40W, Effect 1

Preventive hemostasis

Hemostatic forceps: Eruption from vein: Current supply with distal end only (Forced, 40 W). Vein: Soft Coag., 60 to 50 W.
Artery: Soft Coag., 40 W. Arterial bleeding: Soft Coag., 60 to 50 W. If this cannot stop bleeding, add Forced, 40 W for a few seconds.
*The Forced mode enables instant hemostasis but care is required against scorching and rebleeding. *Soft coagulation wave should not be applied all at once, but should be separated into a few separate applications.
If the patient has a high blood pressure, control it to the normal range. If the water jet function is not available, use an irrigation tube on a 2CH scope. If bleeding cannot be stopped at all, use a clip and supply current.

Perforation measure

Method	Timing	Tip
Clipping	Immediately after discovering perforation.	The procedure may be discontinued as required and resumed on the next day.

The setting values are those determined as of September 1, 2005.

ESD

Endoscopic Submucosal Dissection

— Techniques —

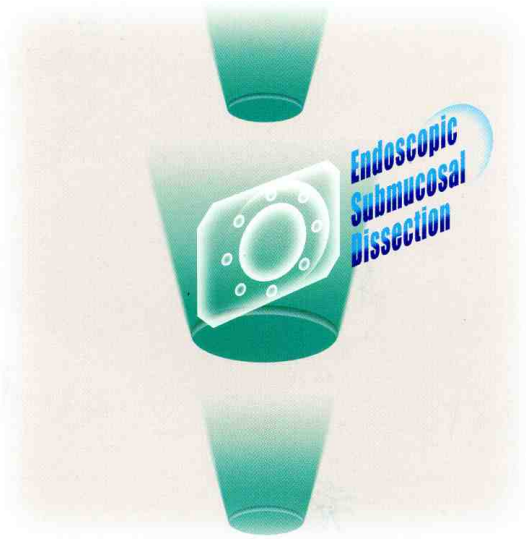

Printed in Japan F1144SB-1005